Right Shoulder (PL61)

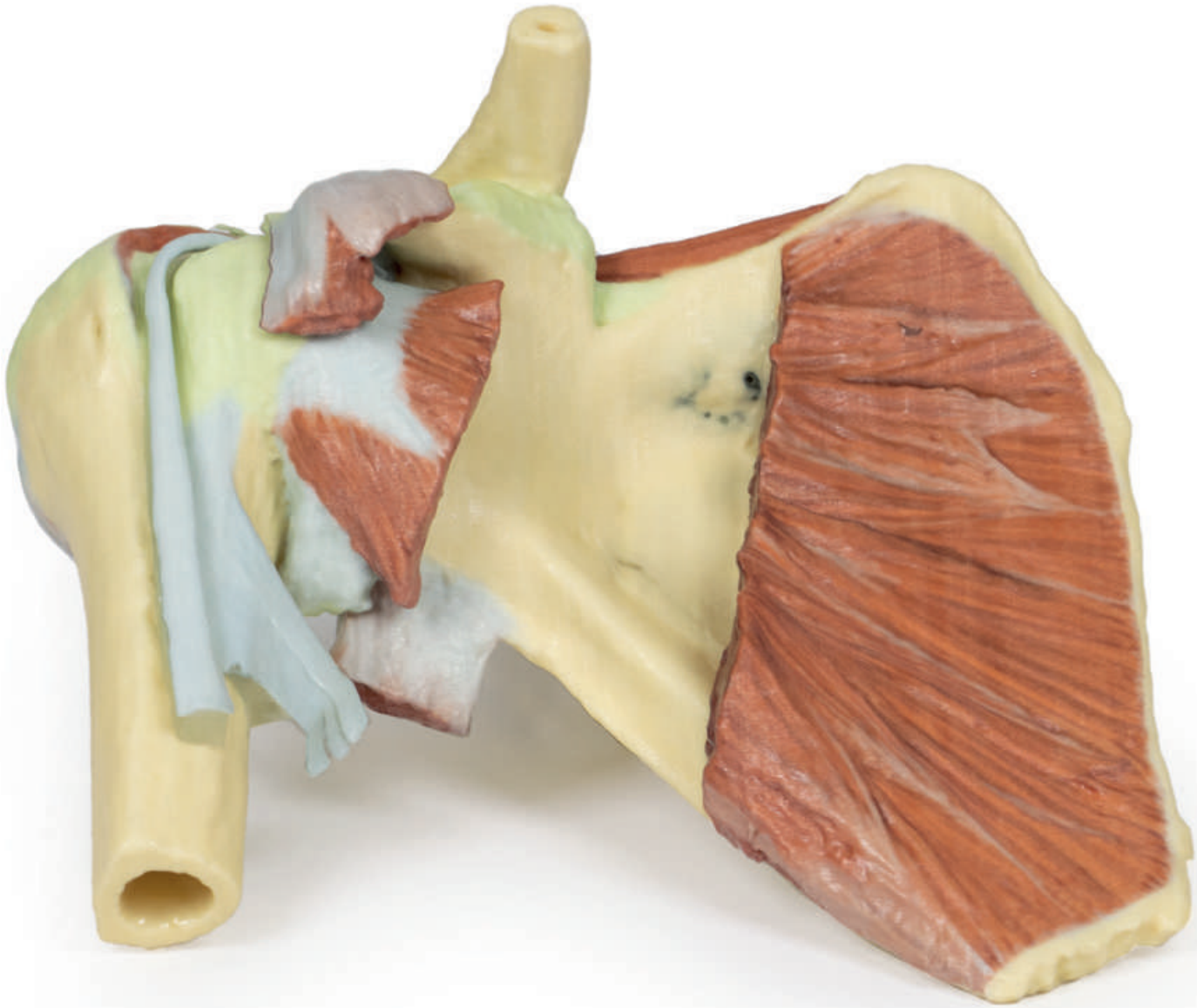

Ref.no.: MP1527

ERLER ZIMMER

Experts in medical education since 1950

Right Shoulder (PL61)

This 3D printed specimens preserves a deep dissection of a right shoulder girdle, preserving a complete scapula, lateral clavicle, and proximal humerus. In the anterior view, the subscapularis muscle is preserved but sectioned to highlight the cross-sectional thickness of the belly within the subscapular fossa. The coracoclavicular ligament and coracoacromial ligaments are preserved just medial to the insertions of the coracobrachialis and pectoralis minor muscles on the coracoid process of the scapula. The insertion of the tendon of the latissimus dorsi is covered by the tendon of the long head of the biceps brachii muscle passing in the bicipital groove towards the glenohumeral joint capsule. The capsule has been opened anteriorly to expose the passage of this tendon, as well as the suprapinatus muscle (covered by the collapsed subdeltoid bursa). In the posterior view the supraspinatus muscle is preserved, with the infraspinatus and teres muscle removed to expose the posterior glenohumeral joint capsule. The insertions of the long head of the triceps brachii, infraspinatus, and teres minor are all preserved.





